

Periorbital postinflammatory hyperpigmentation after plasma exeresis

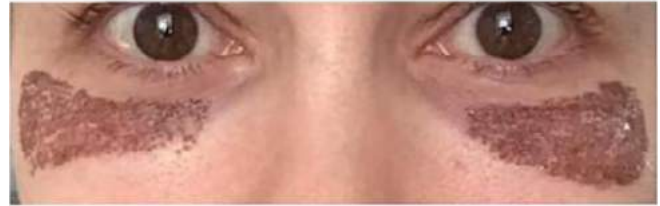Dear Editor

Postinflammatory hyperpigmentation (PIH) developing after cosmetic procedures, such as chemical peeling and laser therapies are always a concern, has not been reported with plasma exeresis (PlexR).

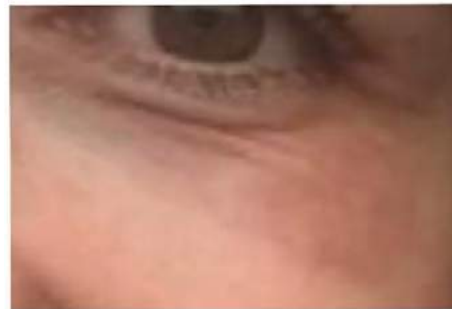Plasma exeresis is considered to be a safe method suitable for all skin types, because of the minimal dermal damage according to the manufacturer and as shown in research.¹⁻³ It is an effective non-surgical treatment as an alternative for surgical upper and lower blepharoplasty. Plasma is formed by this device through the ionization of atmospheric gas. The amount of plasma generated depends on which of the three Plexr devices is used. The white device has 0.7-W power and creates points on the skin with a diameter of 0.5 mm, the green device has 1-W power and creates 1 mm points, and the red device is the strongest with 2-W power and 2 mm points, respectively. This series of minuscule dots on the skin causes an instant tightening and contraction of the skin fibers subsequently leading to remodeling, lifting, and rejuvenating effects. After the treatment, a crust on the treated part will form that falls off in about a week, leaving no bruising or scarring.

Over the last 4 years (March 2016 through February 2020), we have performed 164 nonsurgical upper and lower blepharoplasties using plasma exeresis in 106 patients in our clinic. Sixty-four patients had a single treatment, 31 patients had 2 treatments, 6 patients had 3 treatments, 1 patient had 4 treatments, and 4 patients had 5 treatments. The average time between the treatments was 6 months. Recently, we have had two patients, a 37-year-old woman with Fitzpatrick skin type II (patient 1) and a 61-year-old woman with Fitzpatrick skin type IV (patient 2), who experienced periorbital/periocular PIH after their first plasma exeresis treatment using the red device. In both cases, the brown-colored pigmentation occurred bilaterally after aesthetic plasma exeresis treatment involving the lower periorbital region. It appeared after the natural release of the crust in patient 1 after 6 days and patient 2, respectively, after 9 days. Both patients had no history of allergy as in atopic or allergic contact dermatitis, nor had other dermatological conditions (eg, lichen planus pigmentosus) and did not use any drugs. They applied daily SPF 50 and had no excessive exposure to the sun, nor used a tanning bed.

(A) 1 day after treatment



(B) 6 weeks after treatment



(C) 4 months after treatment

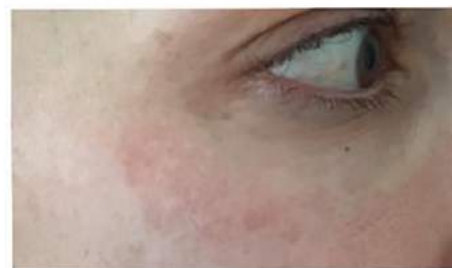
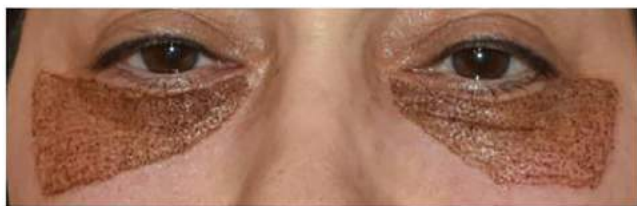
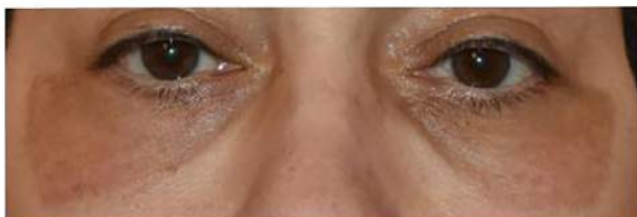FIGURE 1 A, 1 day after treatment. B, 6 weeks after treatment. C, 4 months after treatment

We have prescribed both patients hydroquinone 5% (HQ) in combination with tretinoin 0.05% for bleaching of their hyperpigmented skin after which a mild-to-moderate improvement was reached in both patients. After 4 months, patient 1 was successfully treated with a superficial herbal peel (Green Peel by Dr. Schrammek) and the pigmentation did not re-occur (Figure 1).

(A) Directly after treatment



(B) 1 month after treatment



(C) 9 months after treatment

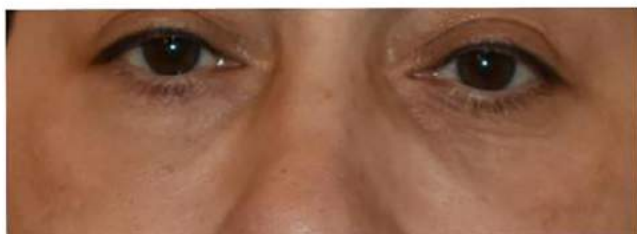

FIGURE 2 A, Directly after treatment. B, 1 month after treatment. C, 9 months after treatment

Patient 2 was treated after 2 months with also the same superficial herbal peel with only minor improvement. Two weeks later, a glycolic acid peeling (Neostrata, 20% glycolic acid) was performed with little further improvement. After this, patient 2 was treated four times with thermomechanical ablation (Tixel on mode 10/500) which resulted in the result as shown in Figure 2C after 9 months. Tixel is a nonlaser fractional treatment technology that transfers thermal energy to the skin through a matrix of tiny pyramid-shaped pins made of biocompatible materials covering a treatment area of 1 cm².


PIH can occur as a side effect of a plasma exeresis treatment in any skin type. Our advice to practitioners is to have their patients apply topical hydroquinone 5% cream each day for 4 weeks prior to plasma exeresis treatment to prevent PIH. Since we have adopted this new protocol, no new cases of PIH after plasma exeresis treatment have occurred.

CONFLICT OF INTEREST

All authors have no conflict of interest.

Martine D. Nipshagen¹

Peter J. Velthuis² 

David G. M. Mosmuller^{1,3} 

¹Doctors At Soap, Private Cosmetic Clinic, Amsterdam, The Netherlands

²Erasmus Medical Center, Department of Dermatology, Rotterdam, The Netherlands

³Department of Plastic, Reconstructive and Hand surgery, University Medical Center Amsterdam, Amsterdam, The Netherlands

Correspondence

David G. M. Mosmuller, Department of Plastic, Reconstructive and Hand surgery, De Boelelaan 1117, 1081 HV Amsterdam, The Netherlands.

Email: davidmosmuller@gmail.com

ORCID

Peter J. Velthuis  <https://orcid.org/0000-0002-9449-0068>

David G. M. Mosmuller  <https://orcid.org/0000-0002-9764-0930>

REFERENCES

1. Sotiris T, Nikolaos G, Irini G. New treatment with plasma Exeresis for non-surgical blepharoplasty. *EC Ophthalmology*. 2017;5(4):156-159.
2. Rossi E, Farnetani F, Trakatelli M, Ciardo S, Pellacani G. Clinical and confocal microscopy study of plasma Exeresis for nonsurgical blepharoplasty of the upper eyelid: a pilot study. *Dermatol Surg*. 2018;44(2):283-290.
3. Tsioumas GS, Georgiadis N, Georgiadou I. The gas ionization by plasma technology for noninvasive techniques in oculoplastic. *JOJ Ophthalmol*. 2017;2(2):555-584.